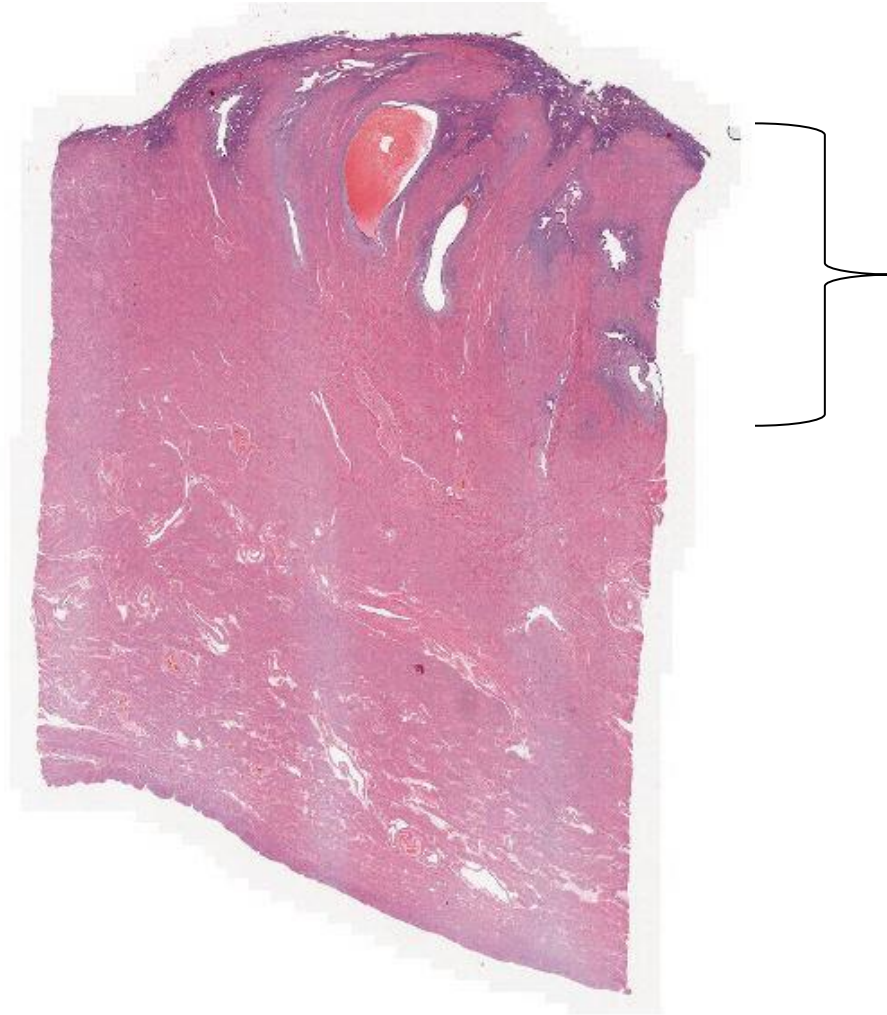
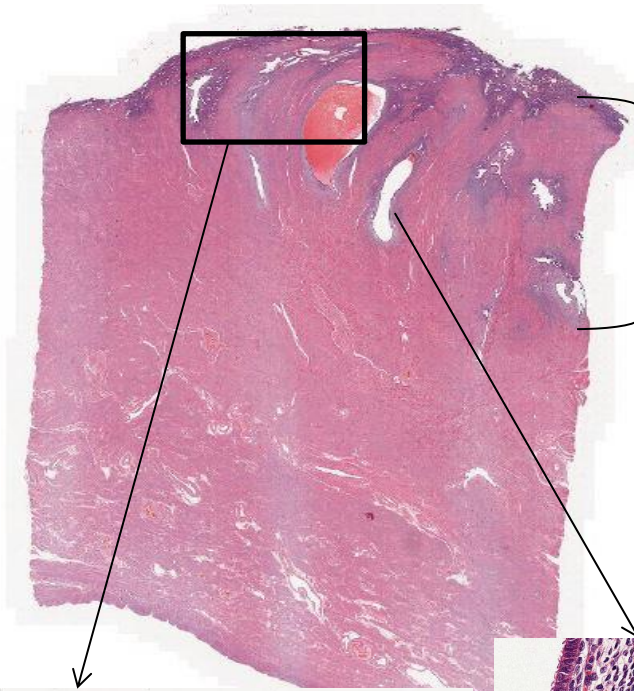


Adenomyosis

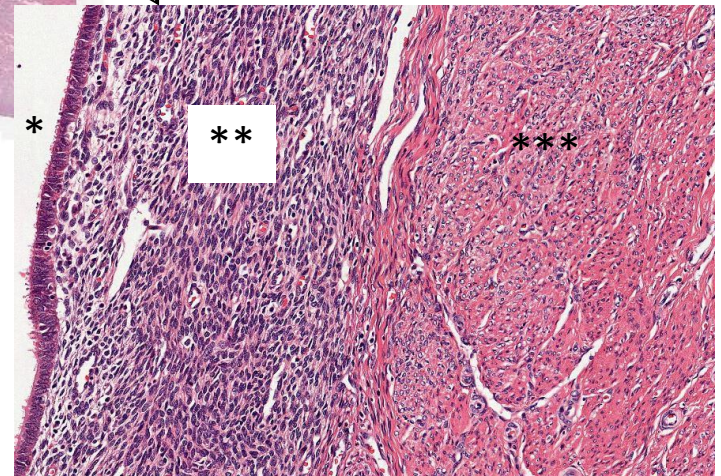
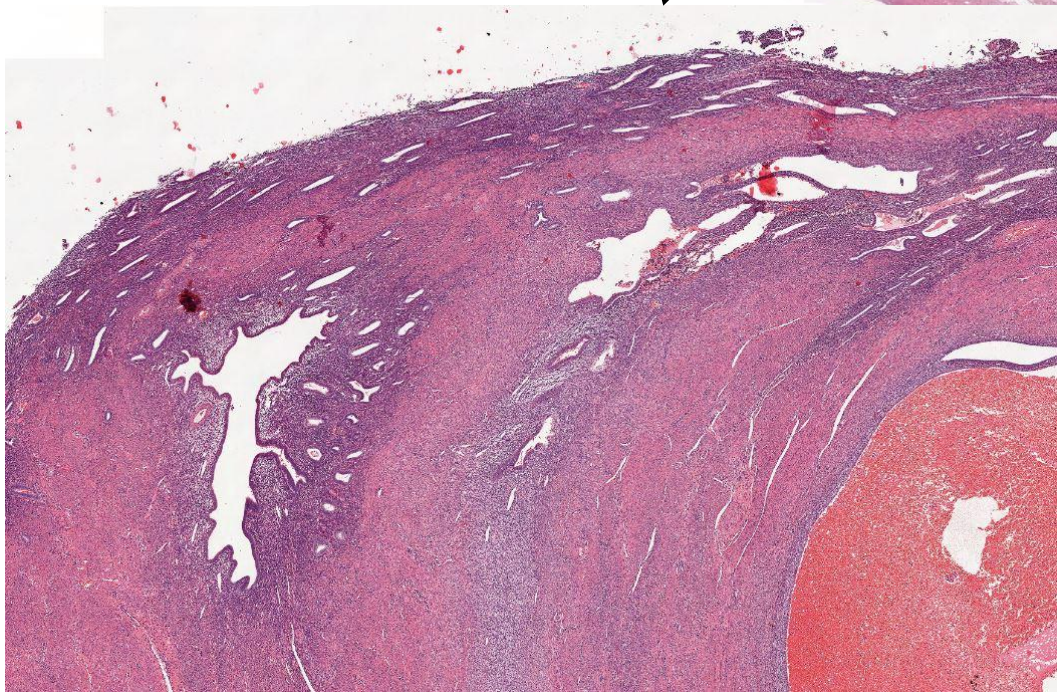


The border of the endometrium?
Look at the stroma surrounding the glands

Adenomyosis



Deep extensions of endometrium into the myometrium, inner half (in this case)



Surface epithelium of em-gland*
Endometrial stroma **
Myometrium***