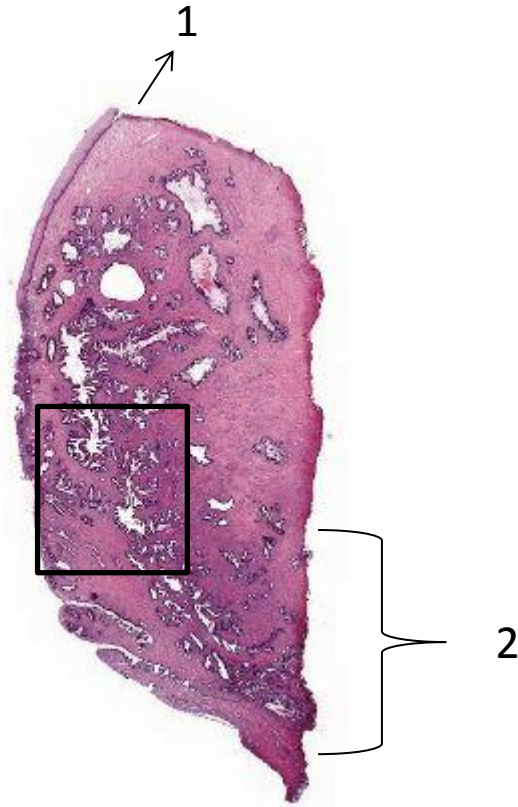


Training case 1, adenocarcinoma /adenocarcinoma in situ of the cervix, cone



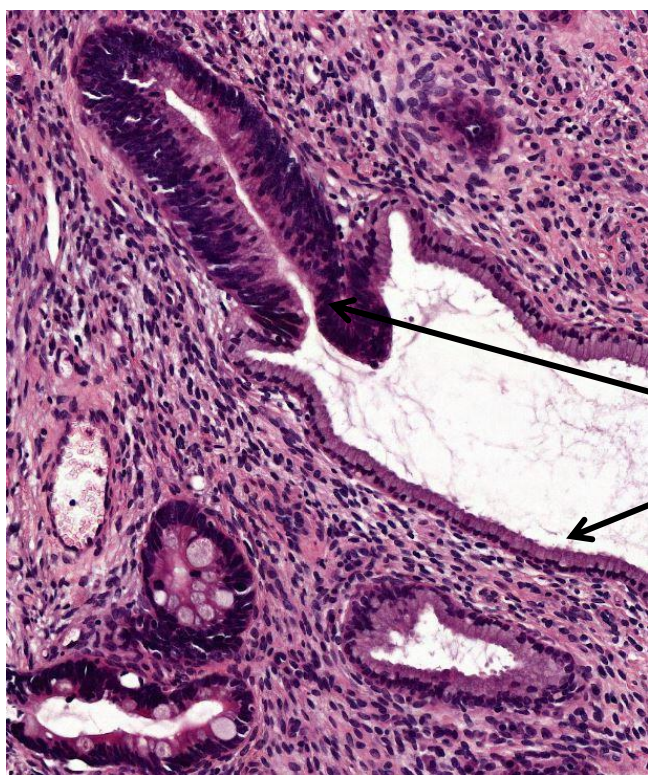
Resection margins? Take a look at the lateral margins.

Identify normal - and atypical glands.

How to describe them?

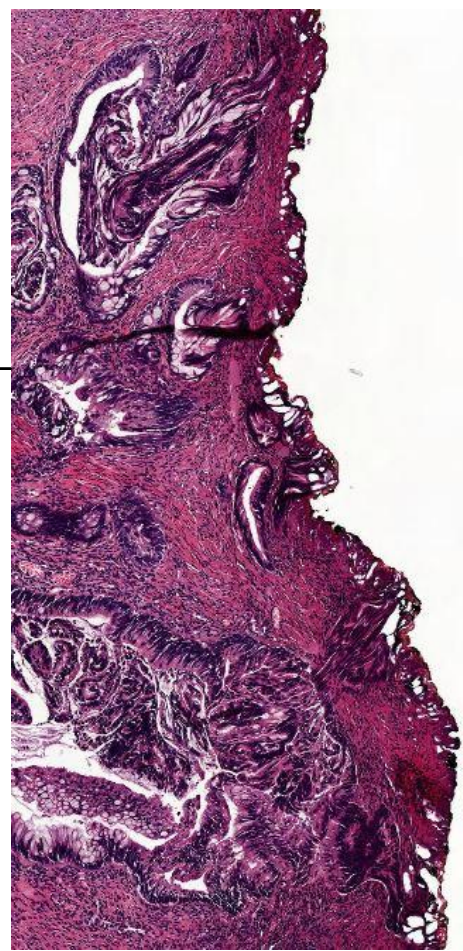
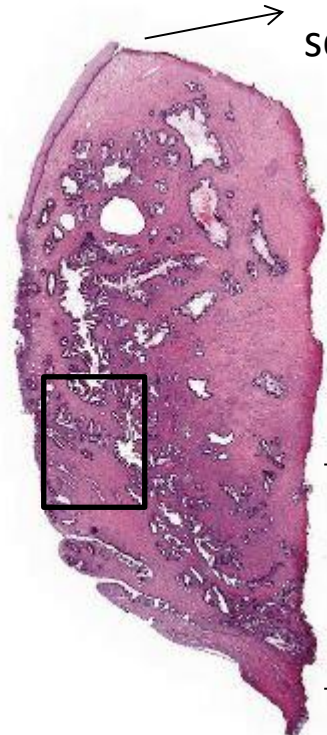
What kind of mucinous cells do you see in normal and atypical glands?

Training case 1, ac /acis

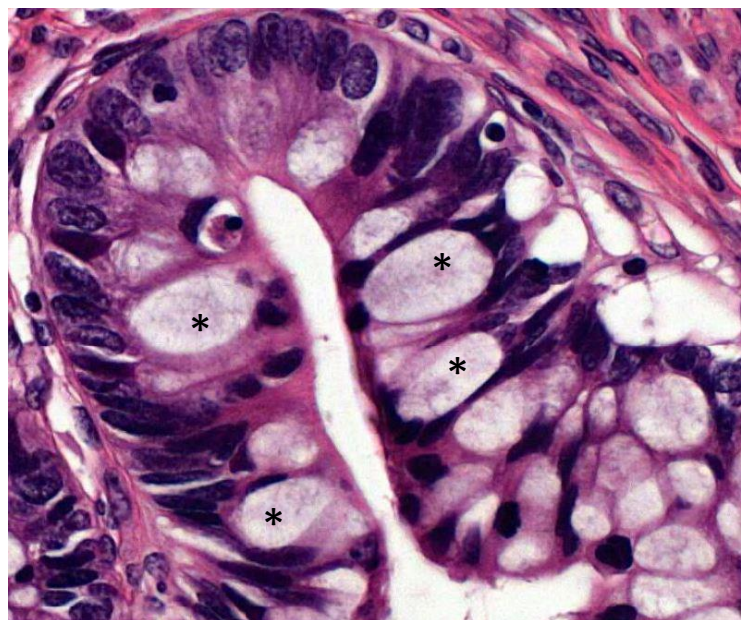


Gland with atypical and normal mucinous epithelium

1. Vaginal end with normal squamous epithelium



2. Atypical glands in lateral resection margins



Atypical gland with goblet cells\*