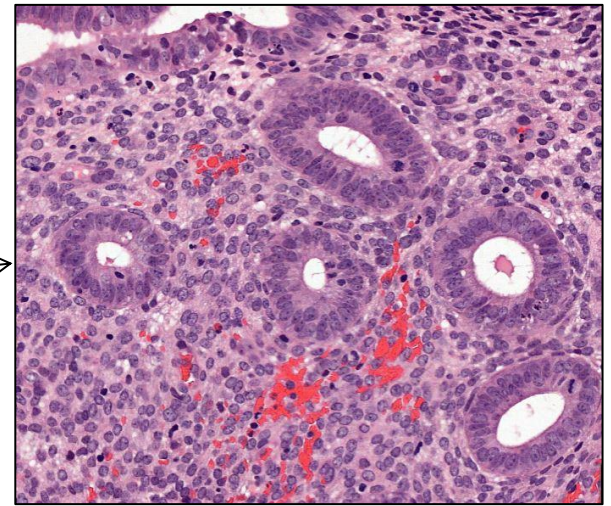
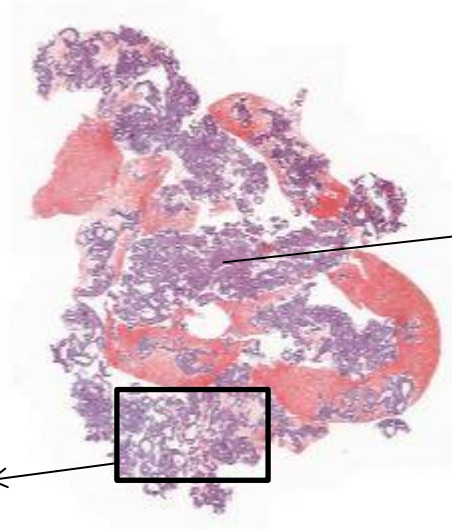
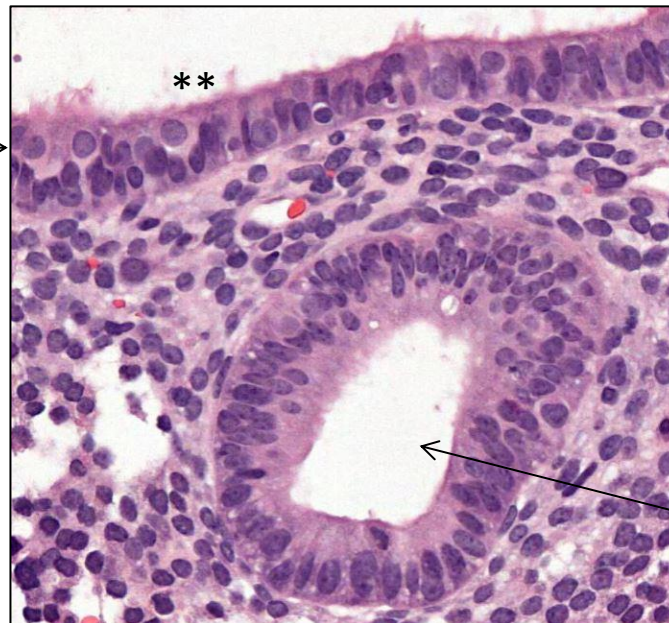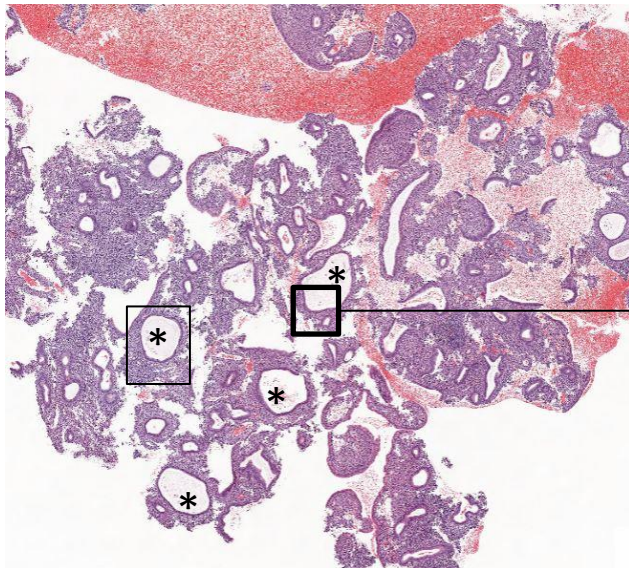


# Hyperplasia

Proliferating endometrium with disorderly arranged, mainly cystic\* glands



Small areas with normal appearing glands



Some cysts are lined by epithelium of serous type; «fallopian-tube type» \*\*

Gland with proliferating epithelium

No distinct cytological atypia