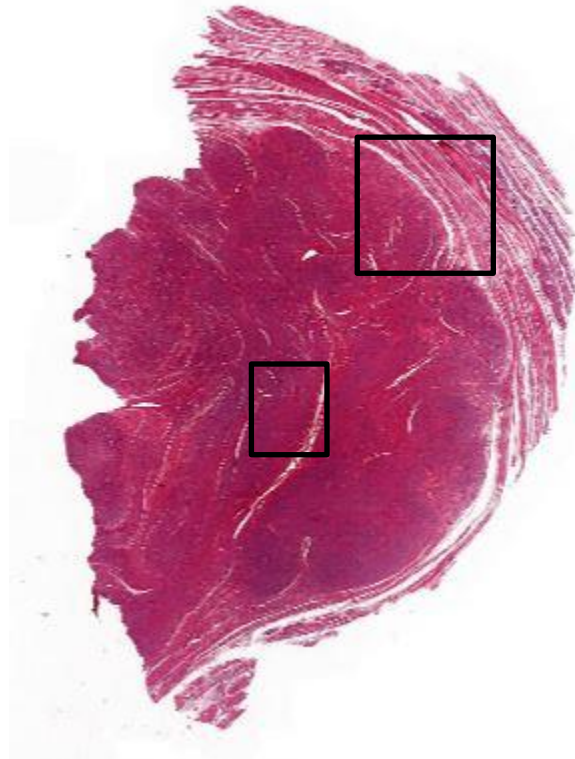
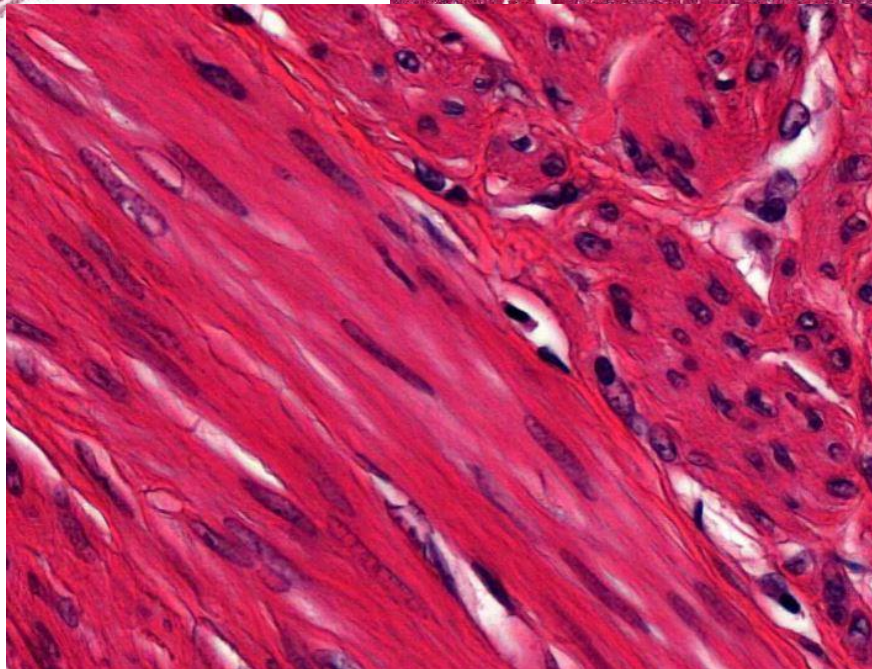
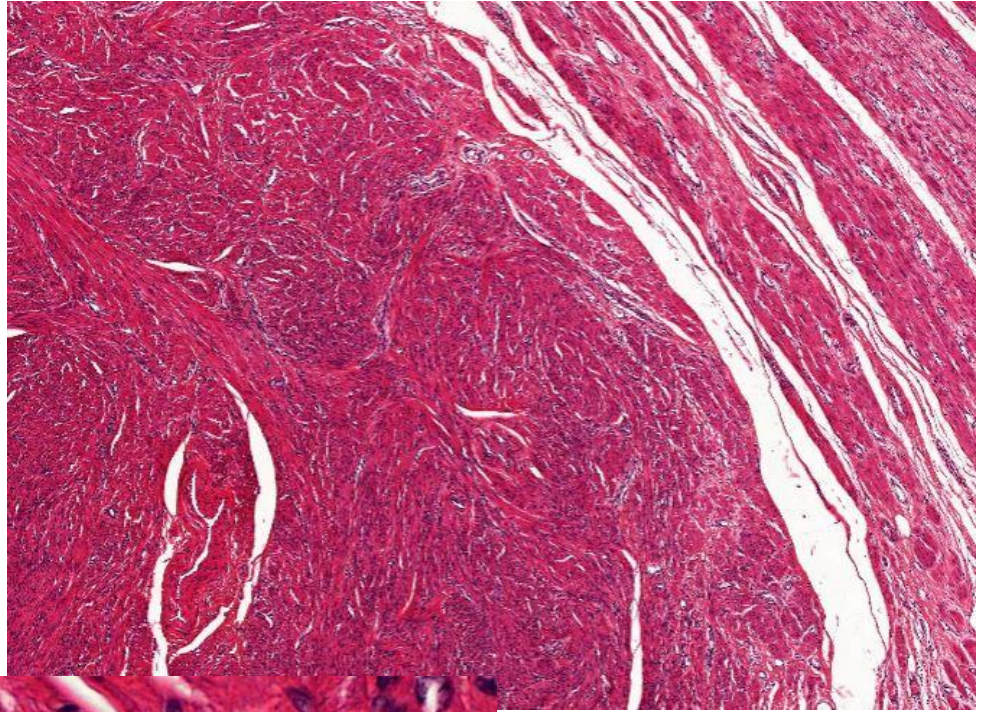
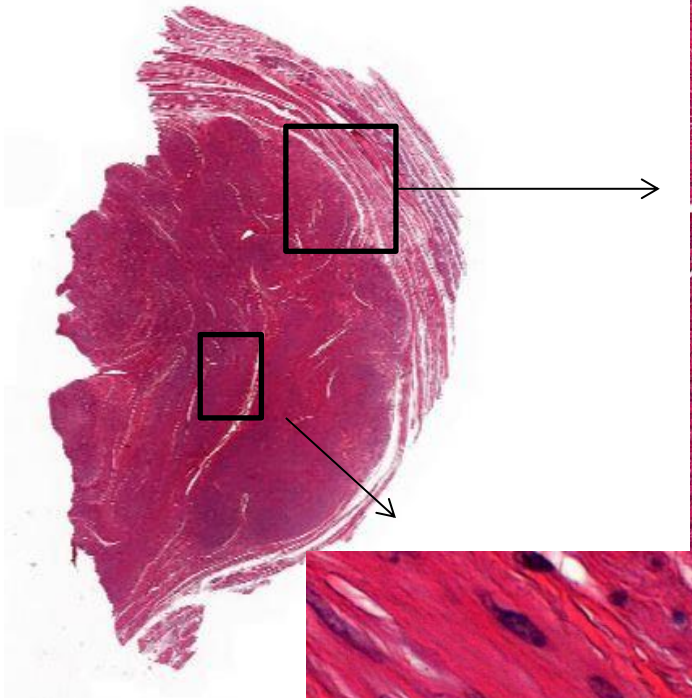


# Leiomyoma



Circumscription?  
Cellularity?  
Atypia?  
Mitoses?

# Leiomyoma



Round, circumscribed nodule. Bundles of smooth muscle cells with cigarshaped nuclei. No mitoses, no variation, no increased density of cells. Hardly any difference to surrounding myometrium.