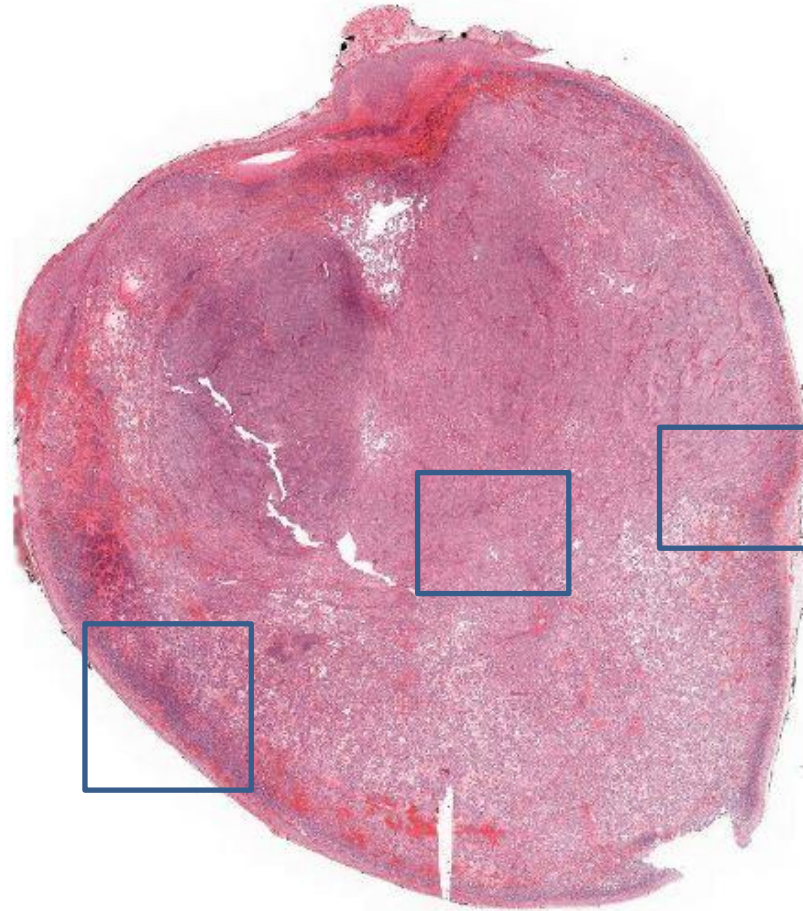
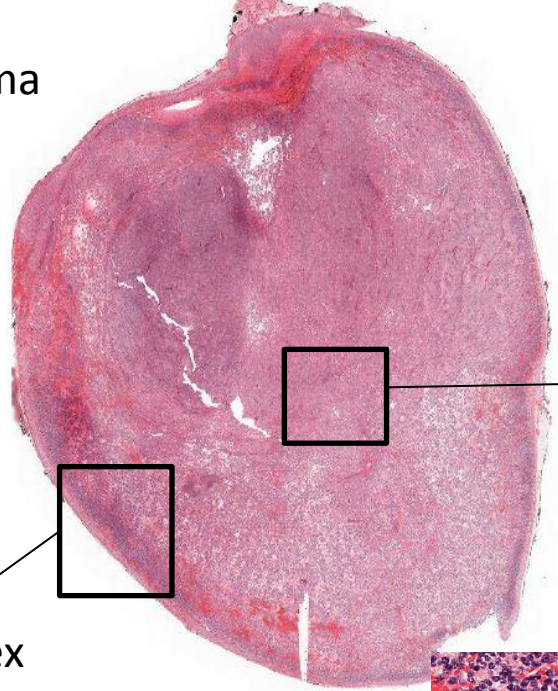


Neuroblastoma

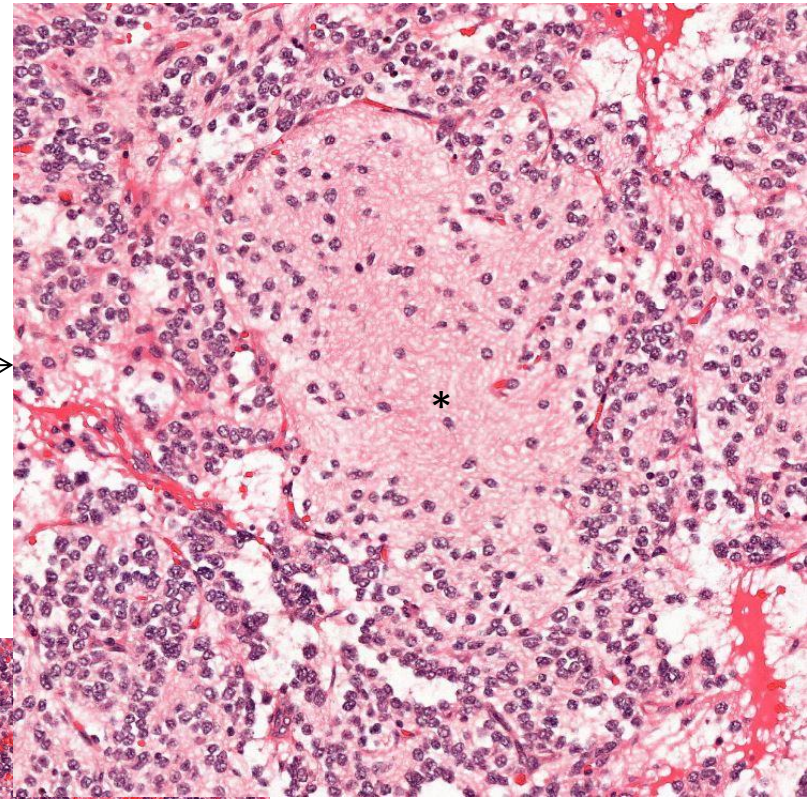
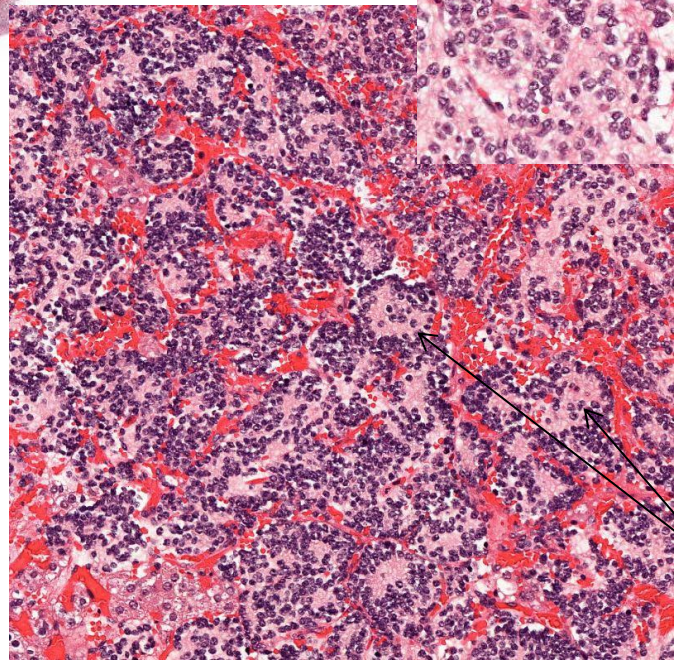
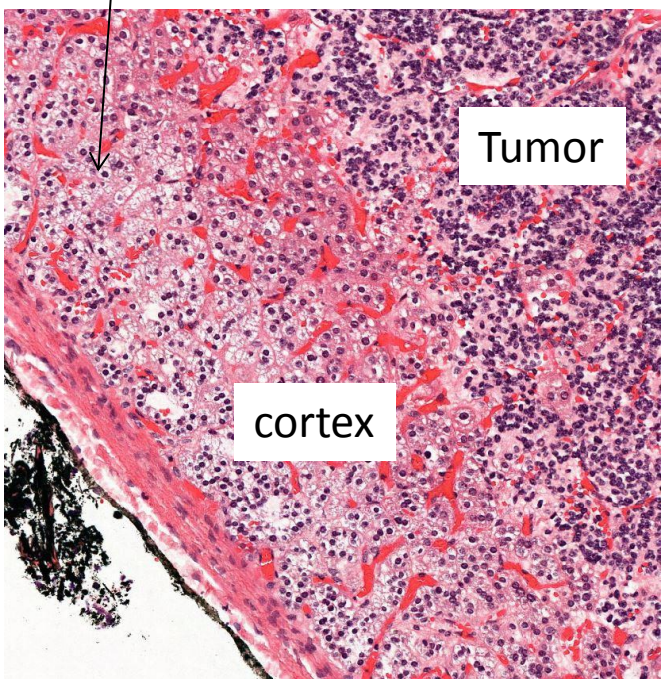


Which organ? Take a look at the borders , normal tissue?
Where in the organ is the tumor located?
Describe the tumor.

Neuroblastoma



Adrenal cortex



Neuroblasts with neuropil * : pink, fibrillar material representing neuritic cell processes

Neuroblasts in numerous rosettes