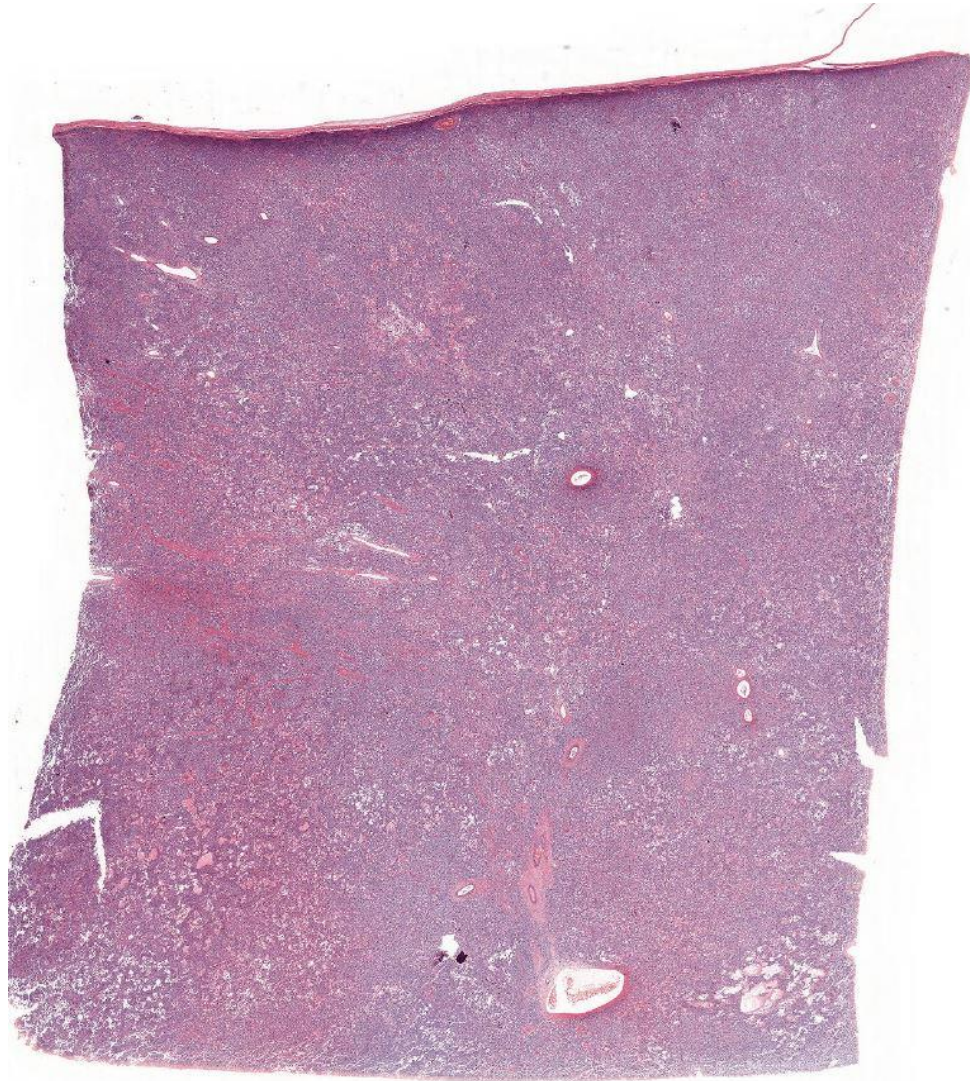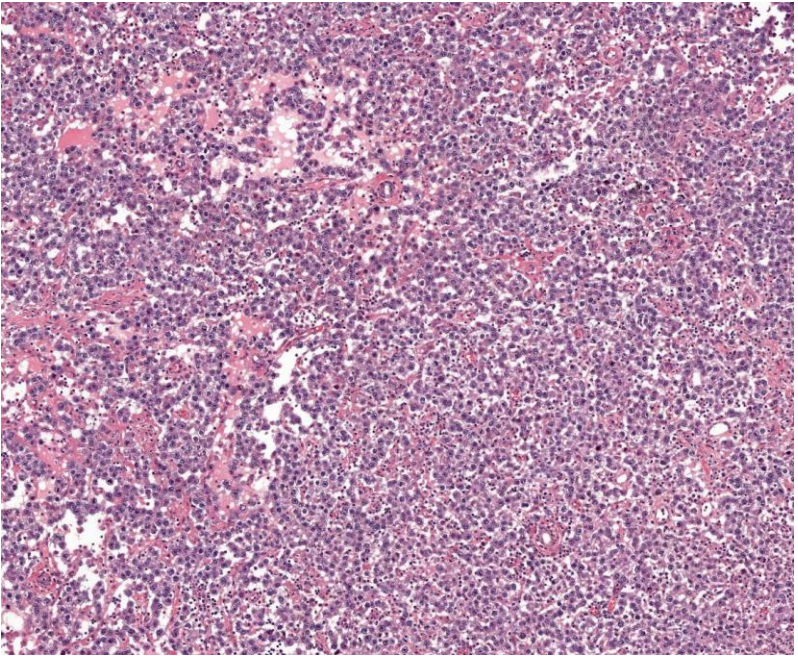


## Dysgerminoma of the ovary

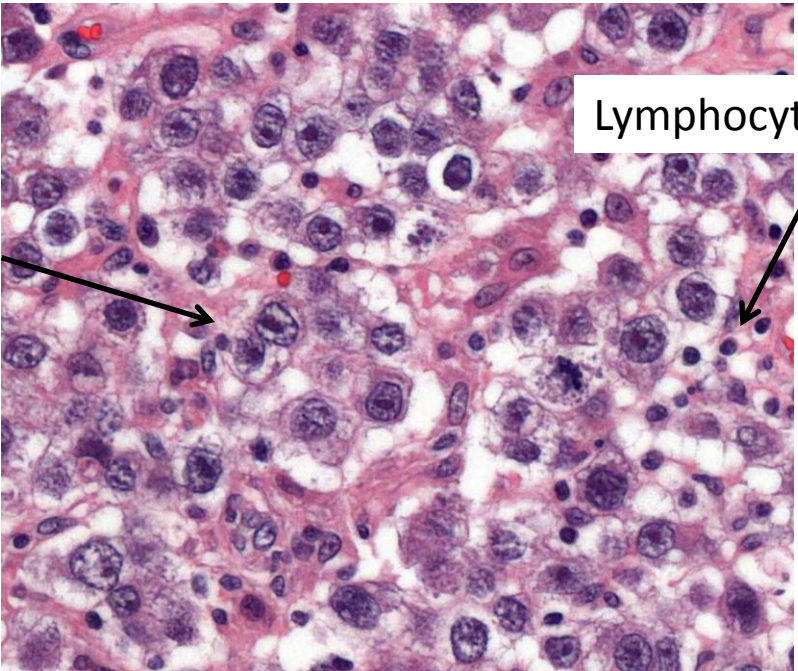
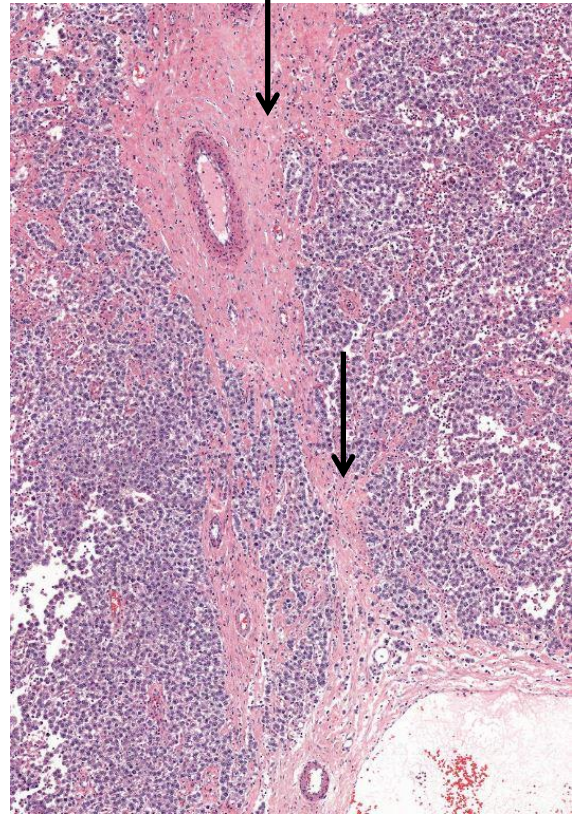


Solid and highly cellular tumor

Atypical tumor cells with large nucleoli and mitoses admixed with small lymphocytes  
Bands of fibrosis



Fibrosis



Lymphocytes

Tumor cells