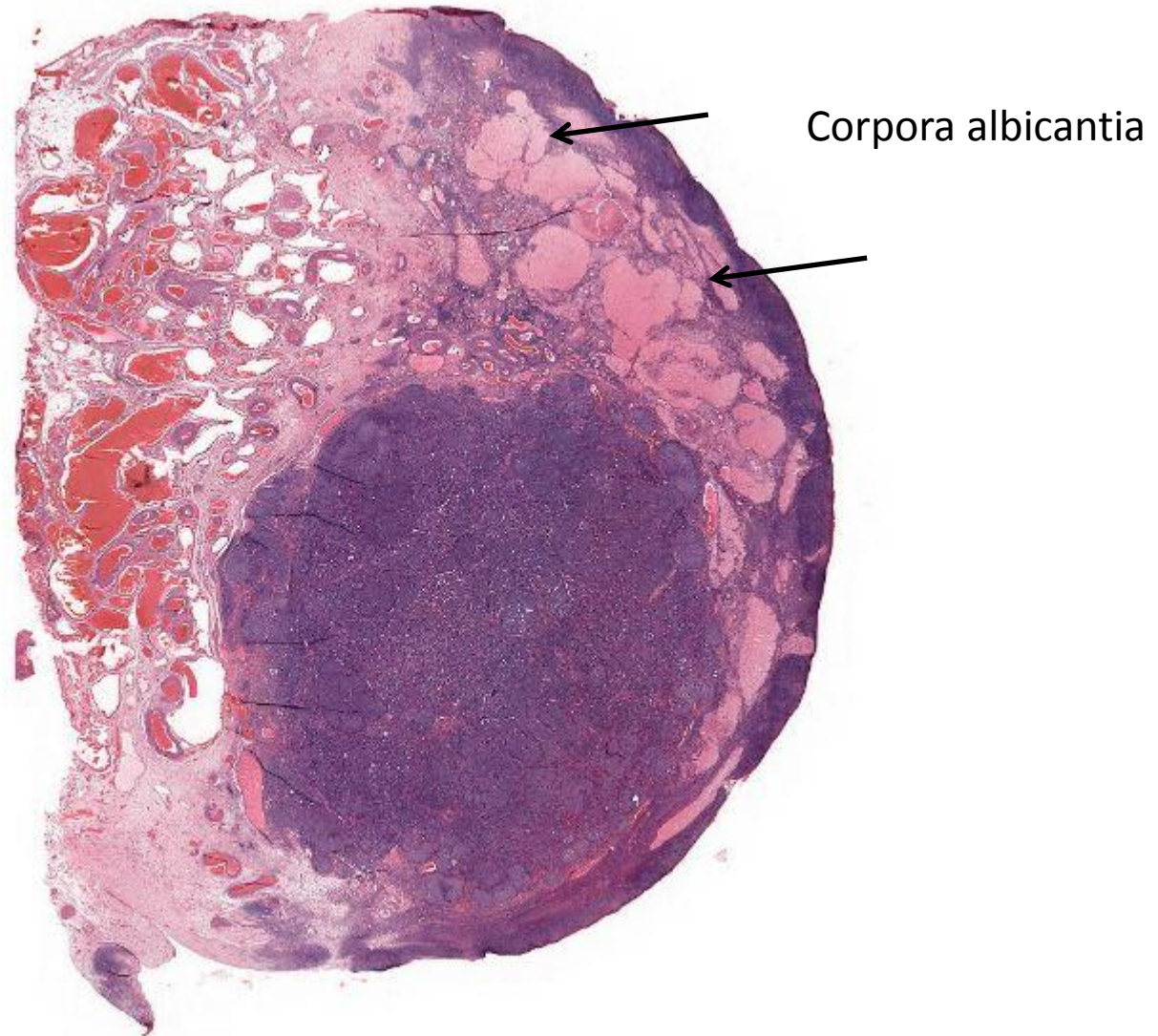


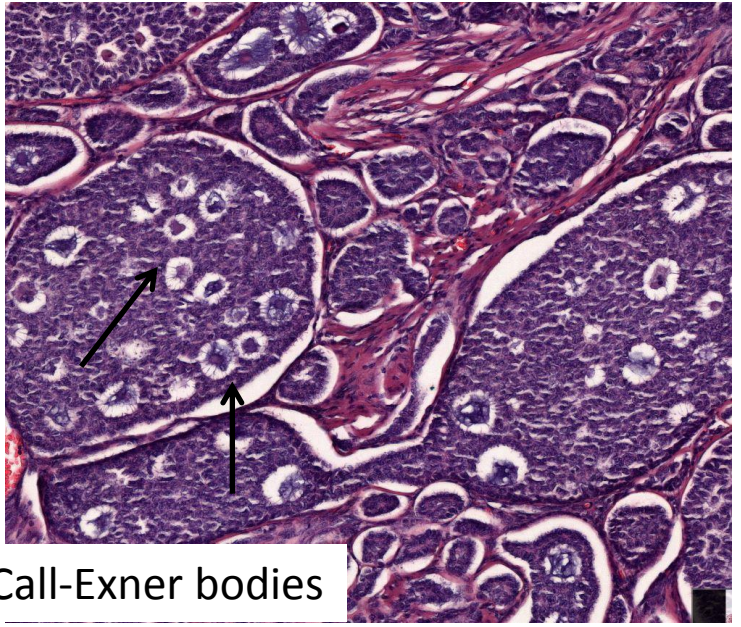
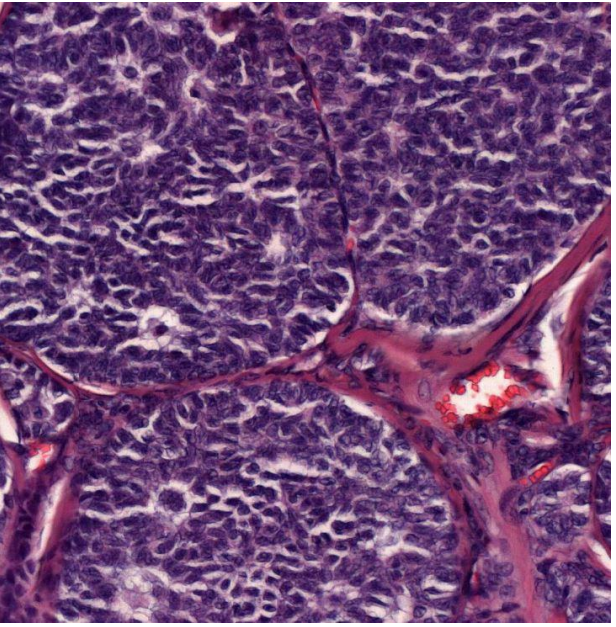
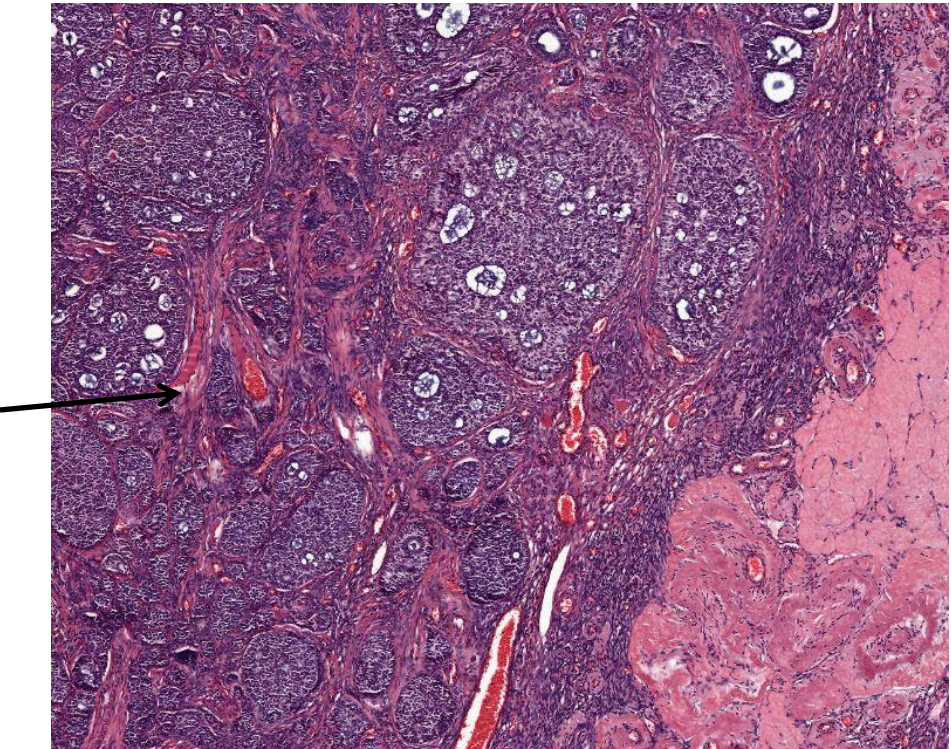
# Granulosa cell tumor of adult type of the ovary



Solid, highly cellular and well-circumscribed tumor

Solid or trabecular growth  
Formation of round spaces with  
eosinophilic material = Call-Exner bodies  
Fibrosis

Fibrosis



Call-Exner bodies