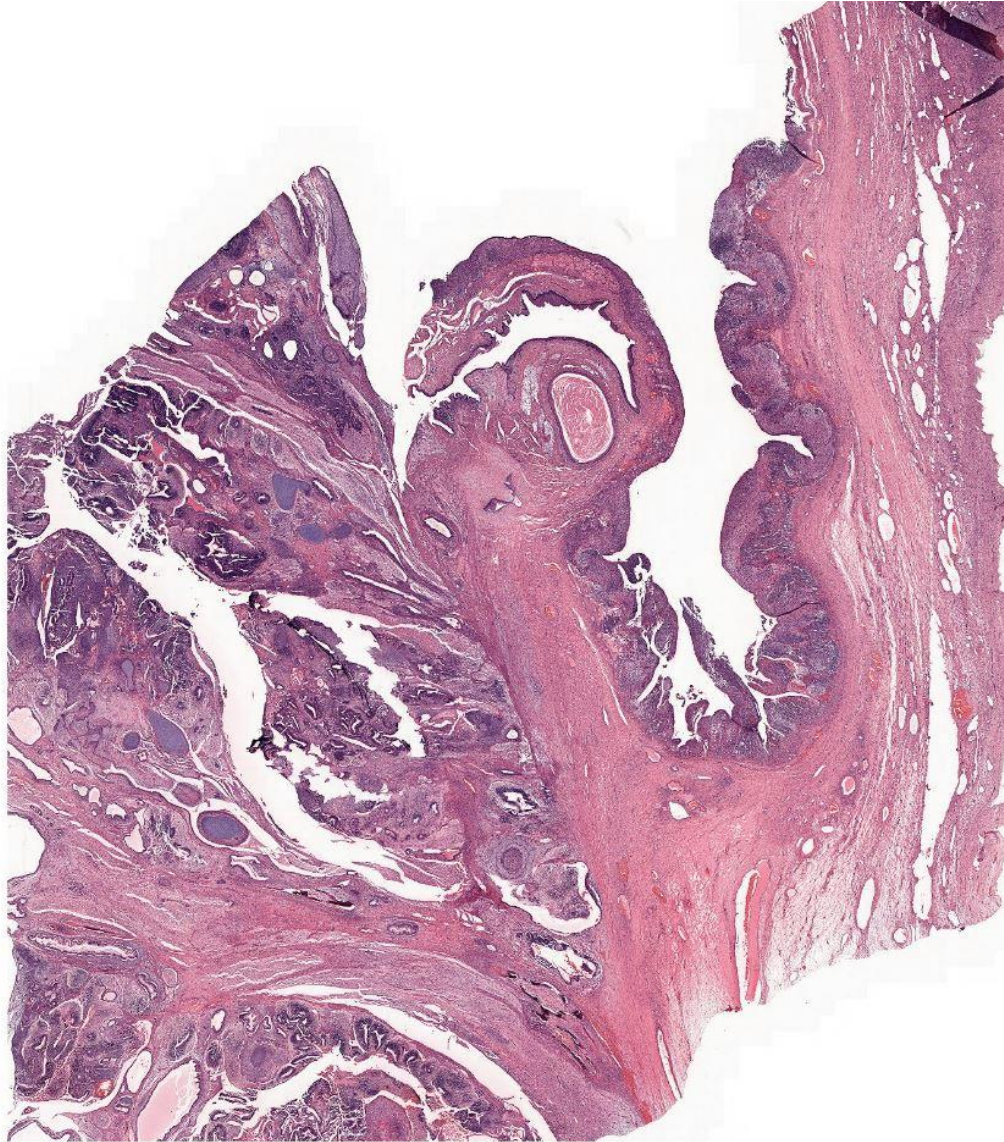


Immature teratoma of the ovary

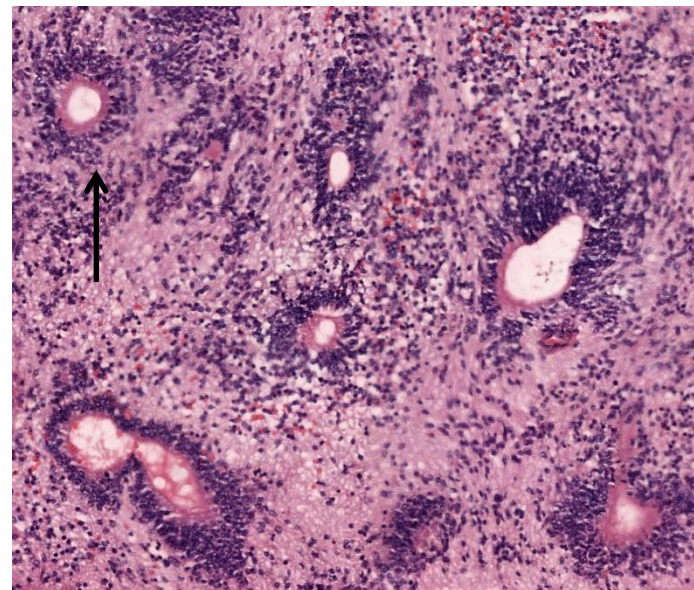
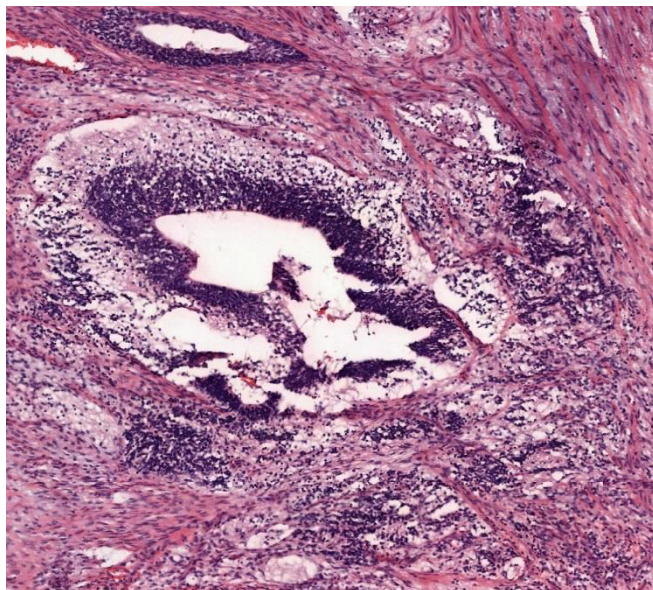
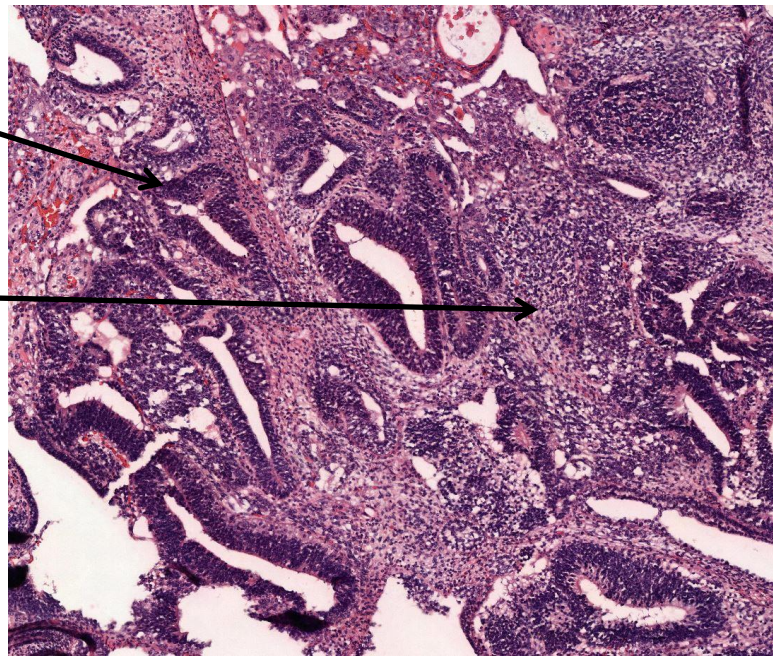


Partly cystic tumor with heterogeneous appearance

Immature tubules

Immature blastema

Immature looking tissue with morphology of neuroectodermal embryonal tissue



Pseudo-rosettes