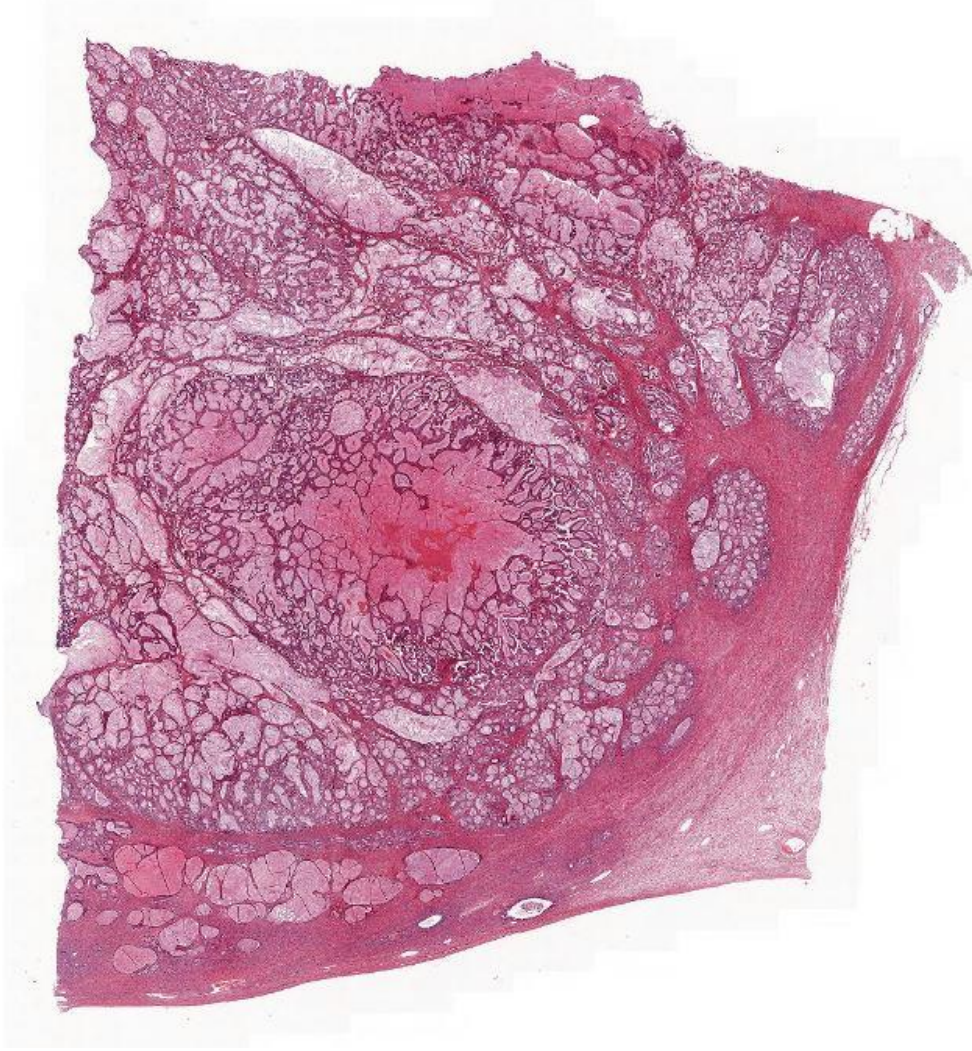
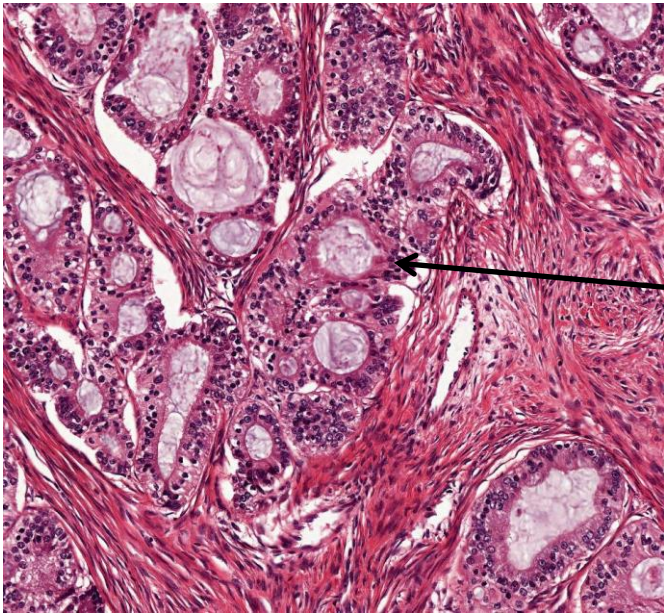


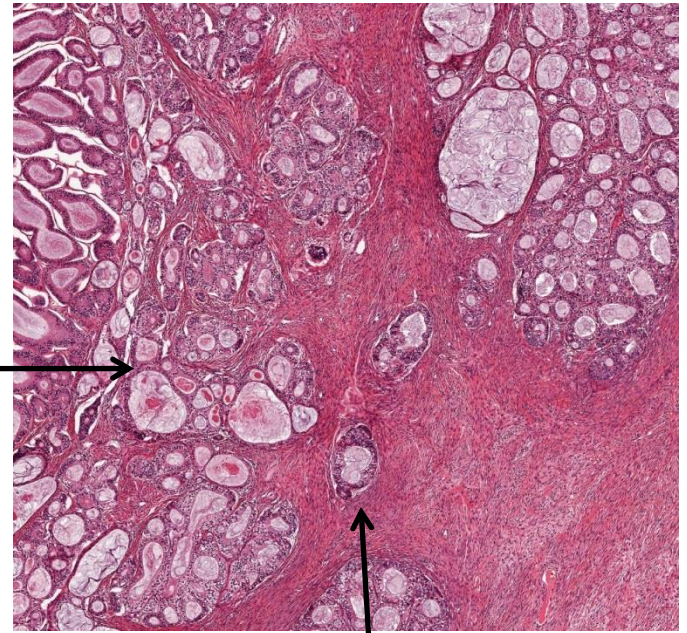
## Mucinous adenocarcinoma of the ovary



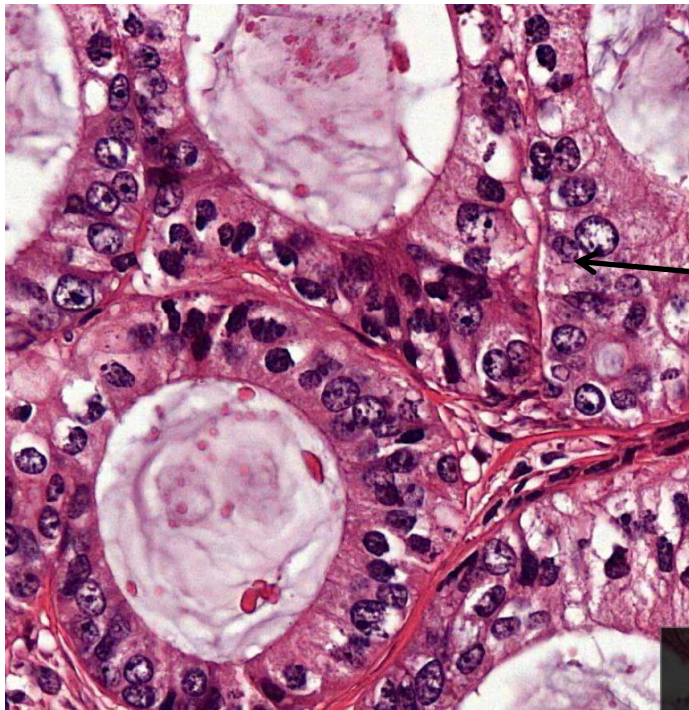
Multiple small cysts with complex epithelial proliferation



Cribriform growth



Stromal invasion



Atypia