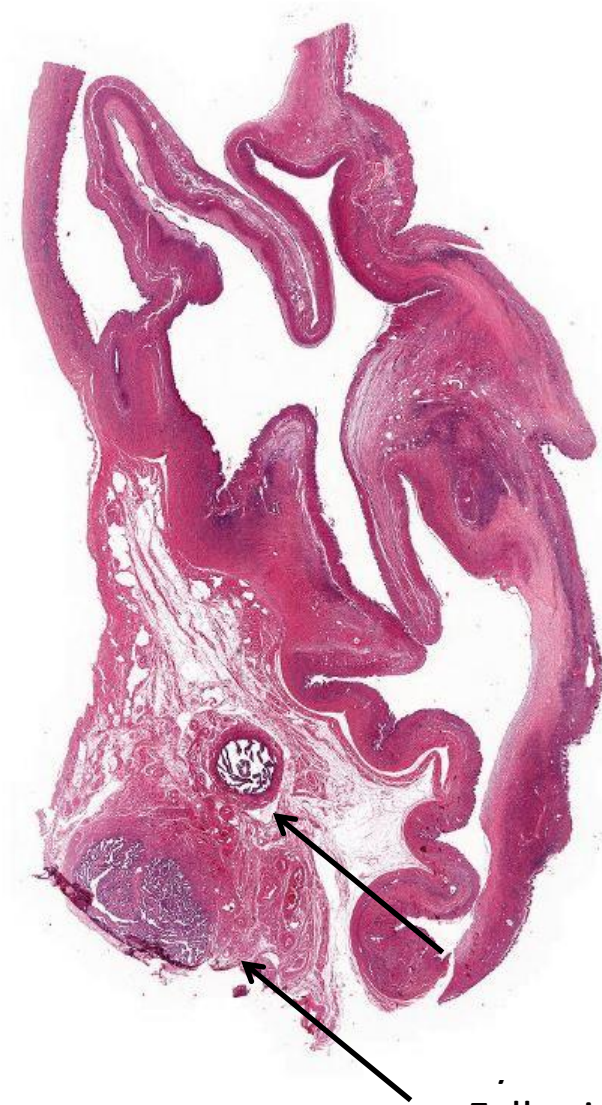
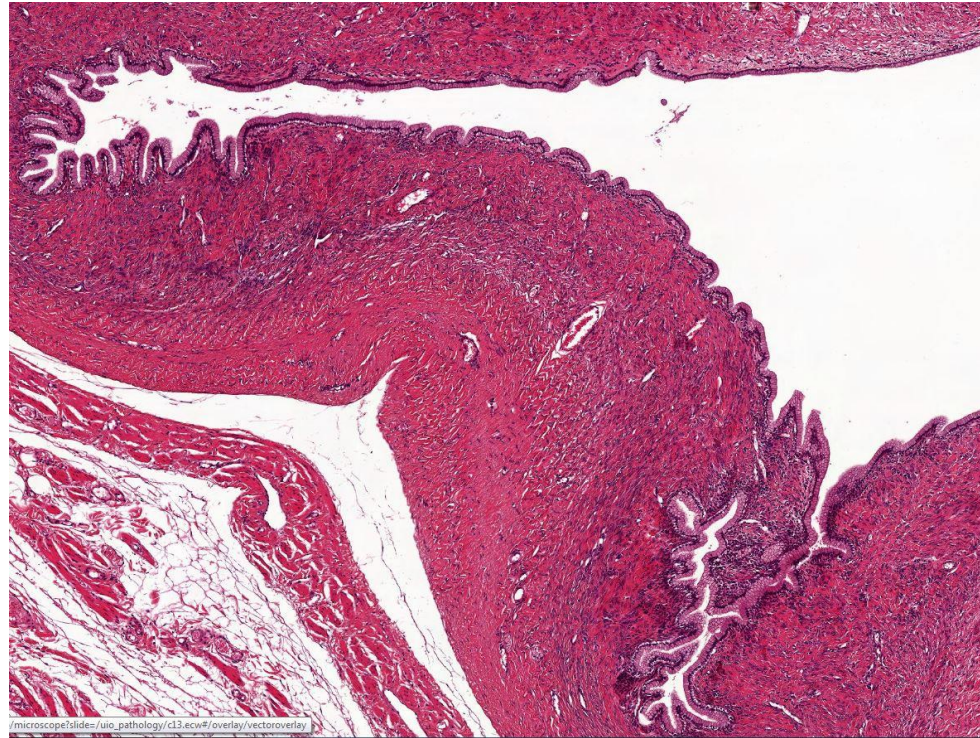


# Mucinous cystadenoma of the ovary



or  
Fallopian tube at left bottom

Single layer of epithelium



Mucinous differentiation  
Basal nuclei  
No atypia  
No mitoses

